

Micro-Fat Graft Associated with Platelet-Rich-Plasma (PRP) for Correction of Depressed Facial Scar

MAURICE FEKRY, M.D.

The Department of Plastic and Reconstructive Surgery, Mataria Teaching Hospital

ABSTRACT

Background: Facial scars are always in sight and can be difficult to hide so become quite distressing and have negative impact to patients so many treatments have been proposed for cosmetic or functional improvement of facial scars. It is known that micro-fat injection have beneficial effects on the remodeling of atrophic facial scar tissue, and platelet-rich plasma (PRP) can be effective during the wound-healing process. We hypothesized that PRP can enhance micro-fat graft survival and the combination would be effective in improving scars appearance.

Objective: The purpose of this study was to evaluate the efficacy of these combinations in the treatment of depressed facial scars.

Patients and Methods: Forty patients with depressed facial scars there were 25 males and 15 females, age range from 18 to 50 years old, during the period From January, 2015 to March, 2016.

Results: We treated with these combination 40 patients affected depressed facial scars. At 6 months the patients' overall satisfaction rate was excellent for over 50% of the patients.

Conclusion: The association of PRP and autologous micro-fat graft are promising and effective therapeutic approach for improvement of depressed facial scars.

Key Words: *Depressed facial scar – Fat graft – Platelet-rich plasma.*

INTRODUCTION

All wounds leave scars, unless they are very small or superficial; depressed facial scars not only lead to cosmetic problems, but also have psychological effects such as emotional debilitation, embarrassment, poor self-esteem, and social isolation [1].

Many techniques are available for the correction of depressed facial scars, including subcision, dermabrasion, chemical peeling, laser technology, fat grafting, and use of fillers; however, these

techniques have resulted in varying degrees of success and associated adverse effects [2,3].

Regenerative medicine is an emerging and rapidly evolving field of research and therapies, the new discovery on stem cells. The discovery of preadipocytes, their mesenchymal origin, and their role as pluripotent stem cells have been used to maintain graft tissue so fat grafting a well-established technique in surgery, became an important tool in regenerative medicine due to the preadipocytes' capability to differentiate and its role in collagen synthesis and angiogenesis. Nevertheless, the major problem remains the ability to maintain fat graft survival and to produce more preadipocytes [4,5].

It has been postulated that autologous platelet-rich plasma (PRP), the α -granules of the platelets release growth factors in response to platelet activation, and stimulate cell proliferation and cell differentiation for tissue regeneration. These growth factors have an important role in the regulation and proliferation of mesenchymal cells, including fibroblasts and have been shown to reduce healing time and improve the likelihood of complete wound healing so PRP can promote the proliferation of human adipose-derived stem cells, so used for the treatment of depressed facial scars, because it can enhance wound healing, which has been shown to accelerate tissue repair [6,7].

The possible mechanism of PRP in the reconstruction of a depressed scar is by promoting the numerous growth factors present in PRP, especially platelet-derived growth factor. This growth factor may help stimulate the production of other growth factors important in tissue remodeling, which promote connective tissue healing by upregulating collagen and protein synthesis [8,9].

PATIENTS AND METHODS

Between January, 2015 and March, 2016, 40 patients were enrolled in the study, with depressed facial scars post-traumatic. There were 25 males and 15 females, age range from 18 to 50 years old, with the mean age of 27.2 years. All the patients gave an informed consent, their full medical history and were photographed before and after the treatment. Their skin type ranged between III and IV on Fitzpatrick scale.

The procedure for the fat harvesting and lipo-filling was as it follows:

- Marking the donor and treatment sites.
- Harvesting fat from the flanks, the lower abdomen or the medial side of thigh and knee with 3mm liposuction cannula connected to 60cc syringe with screw lock, the fat was aspirated by steady to and fro movements in subcutaneous tissue, till the desired amount was aspirated (Fig. 2). Adipocyte viability decreases with increasing negative suction pressure. Thus, mechanical liposuction by machine should be avoided (~500mmHg), and only manual harvesting offers a satisfied fat graft quality.

The syringe of aspirated fat was held with its nozzle downward for 15 minutes so that the solution was settled by gravity and supernatant fat layer was separated then the remaining fluids were discarded. The most used is a blunt tip cannula with a single distal opening of 2mm diameter. The marofat converted to microfat by movements of fat by using two syringes with screw lock and connector in between (Fig. 4).

Perform fat transplantation (lipofilling) to the marked areas with a 1cc syringe and a cannula as small as 0.7mm in diameter so called microfat placing small droplets of fat in the tissue (injected of combination micro fat 80% and PRP 20% in deep dermal layer of the skin with 23 gauge), Coleman's Lipostructure technique [9].

For an activated platelet rich plasma we used a standard PRP from 8.5cc patient' blood up to 2cc PRP it was obtained after 2 centrifugations at 3000rpm for 5min, and activated with calcium chloride 0.1ml for each 1ml. They were injected in the mid and deep dermis Fig. (3). During the initial burst of activity within the first hour, about 95% of the presynthesized growth factors were released, and during the remaining 7 days of their viability, the platelets were synthesized together with the secret additional growth factors.

The procedure was generally performed under local anesthesia and IV sedation (65%) and orotracheal intubation anesthesia (35%). All the patients followed a pre- and post- operating protocol. The postoperative process consisted of antibiotic and non-steroidal anti-inflammatory drug therapy and compressive dressings for the harvesting place (24-48 hours). The patients were hospitalized for 1 day; the follow-up took place after 1 week, 1, 3, 6 months.

RESULTS

Results were gathered through photographs and the following aspects were assessed on a 4-point scale as excellent, good, fair, and poor: Scar appearance, skin condition, symptoms, edema, ecchymosis, and recovery time (Table 1).

The clinic results gradually improved over time postoperatively. Results of patient satisfaction survey.

There were no important complications seen in this series. No infection, fat cysts, granulomas, or other unwanted side effects were observed.

We treated with these combination 40 patients affected depressed facial scars. At 6 months the patients' overall satisfaction rate was excellent for over 50% of the patients (Fig. 1).

Table (1): Post-treatment assessment of patient satisfaction rate at 6 months.

	Poor	Fair	Good	Excellent
(1) Scar	1	5	12	22
(2) Skin Condition	0	3	13	24
(3) Symptoms	1	2	14	23
(4) Oedema	3	8	11	18
(5) Ecchymosis	4	7	10	19
(6) Recovery Time	3	5	12	20

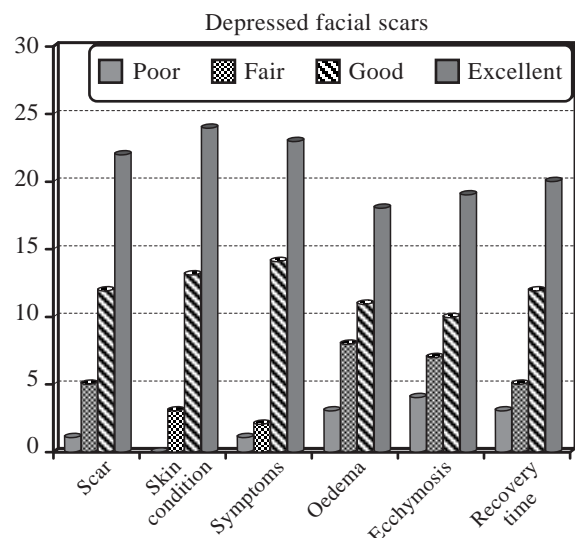


Fig. (1): Patient evaluation in depressed facial scars.

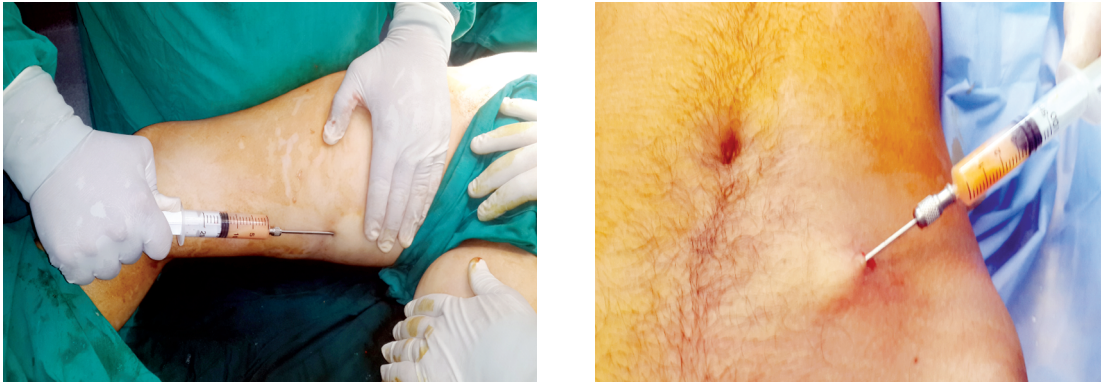

Fig. (2): Harvesting fat from the medial side of the thigh and the lower abdomen.

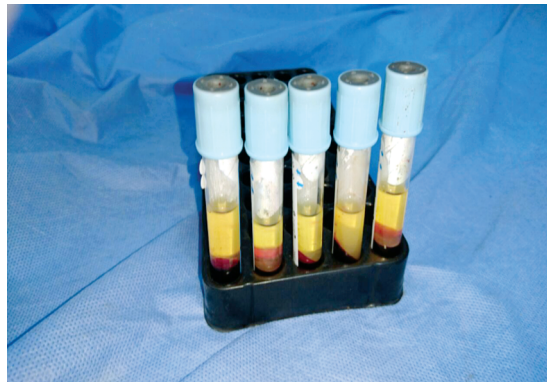

Fig. (3):
PRP preparation.

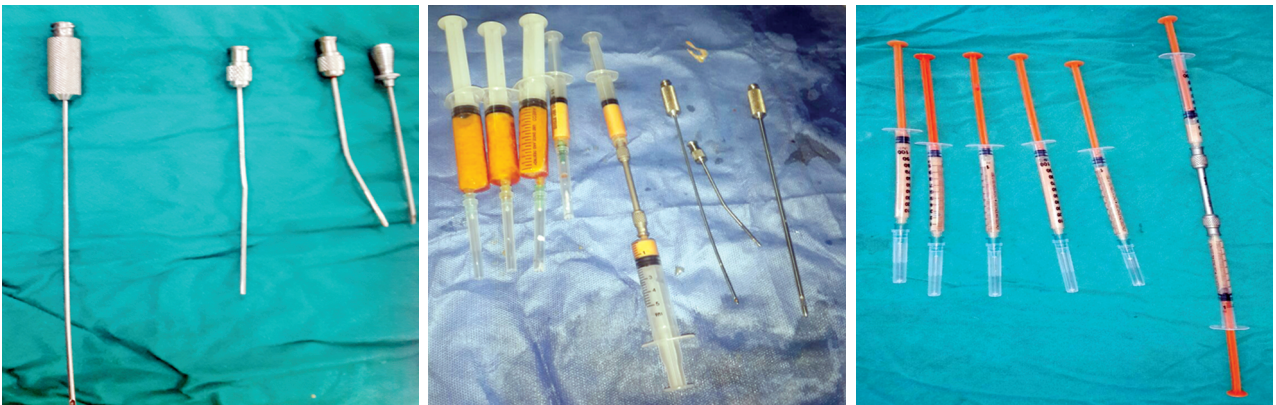

Fig. (4): Preparation of micro fat.

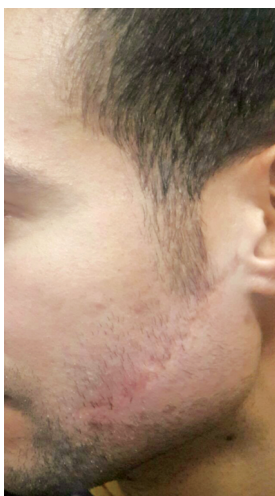

Fig. (5-A):
Preoperative.

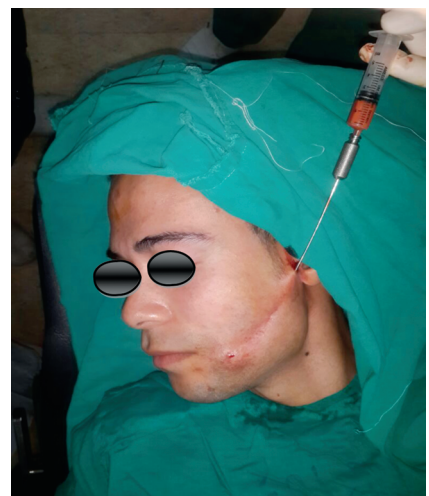

Fig. (5-B):
Injection of micro fat.

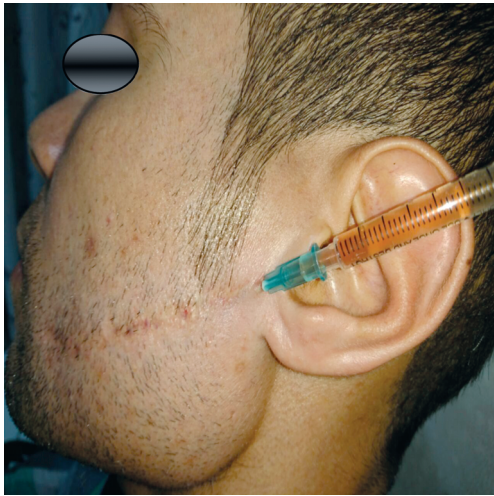


Fig. (5-C): PRP injection.

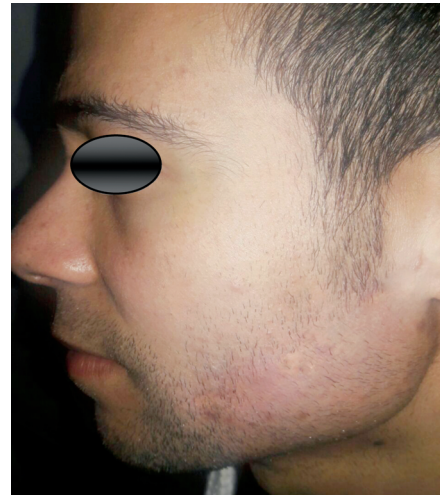


Fig. (5-D): Post-operative.

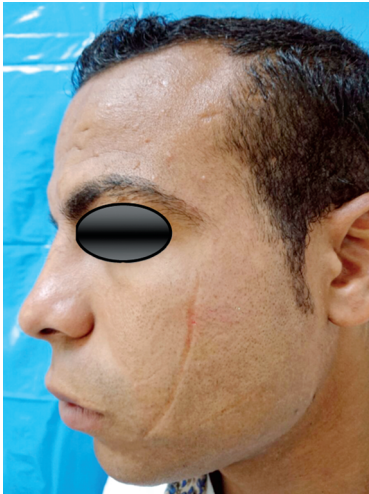

Fig. (6-A): Pre-operative.

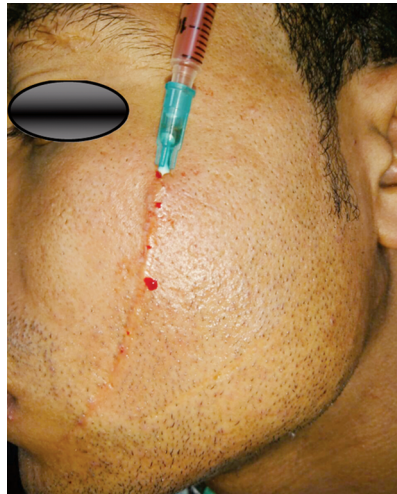


Fig. (6-B): PRP injection.

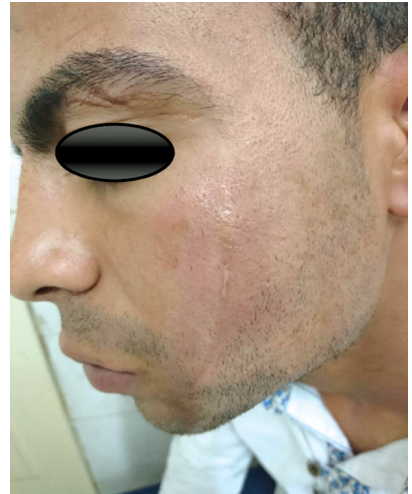

Fig. (6-C): Post-operative.

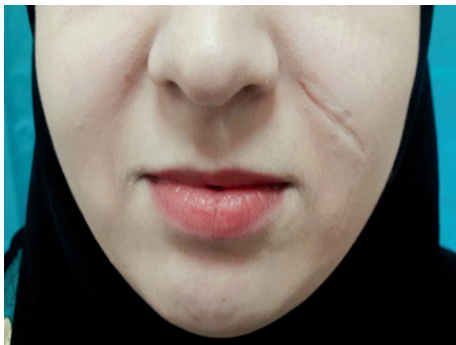


Fig. (7-A):
Pre-operative.

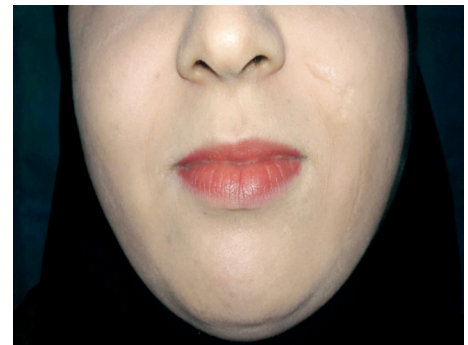


Fig. (7-B):
Post-operative.

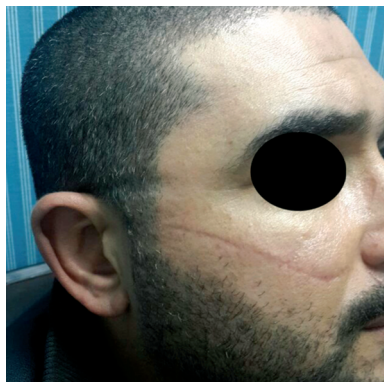

Fig. (8-A):
Pre-operative.

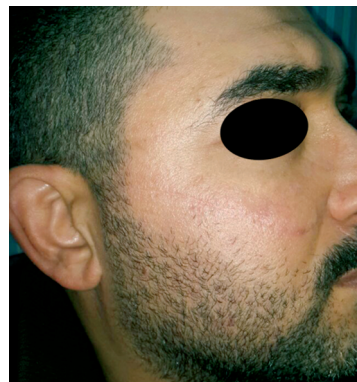

Fig. (8-B):
Post-operative.

DISCUSSION

Facial scarring has always been a challenge to treat. There are different modalities for the management of these scars including various types of resurfacing which have the disadvantages of either being too mild and ineffective or being too aggressive and complicated [1].

Autologous fat transfer has enjoyed a renaissance in the last several years. In particular, the micro droplet approach offers the surgeon an opportunity to address superficial skin problems such as scars [10].

Micro fat transfer offers many of qualities of ideal soft tissue filler: It is biocompatible, inexpensive, readily available, and non-migratory with long term results. However, even with the best technique, the survival rate is still quite variable and unpredictable. The addition of PRP to fat grafts represents several advantages with a simple, cost-effective and safe method [11,12].

Injected of combination micro fat 80% and PRP 20% in deep dermal layer of the skin with 23 gauge, Coleman's Lipostructure technique, offers better fat grafting survival, Less bruising and inflammation, and Easier application of fat grafts due to liquefaction effect of PRP with another injection of PRP in the mid and deep dermal layer of the skin in repeated multiple (2-3) sessions after one month from combination therapy and this technique gave good results from used combination only [13,14,15].

Based on the recent data released by Cervelli on the role of platelet growth factors in accelerating the healing entitled us to assign in this technique. The immediate effect was to shorten the healing time and increase the graft survival for in improvement of depressed facial scar [11].

Regarding the patients' overall satisfaction rate, over 50% rated the treatment as excellent. The most symptom was post lipofilling edema, lasting in some cases, up to 1 month and this finding consistent with the other study [13,14].

Conclusion:

We concluded that the addition of PRP to micro fat injection offers several advantages including Better fat grafting survival, Less bruising and inflammation, and Easier application of fat grafts due to liquefaction effect of PRP so that micro fat

injection with PRP might become a new concept in improvement of depressed facial scar.

REFERENCES

- 1- Cooper J.S. and Lee B.T.: Treatment of facial scarring: Lasers, filler, and nonoperative techniques. *Facial Plast. Surg.*, 25: 311-315, 2009.
- 2- Ganio C., Tenewitz F.E., Wilson R.C. and Moyles B.G.: The treatment of chronic nonhealing wounds using autologous platelet-derived growth factors. *J. Foot Ankle Surg.*, 32: 263-268, 1993.
- 3- Sund B.: Compiler. In: *New Developments in Wound Care*. London: PJB Publications, pp. 1-255, 2001.
- 4- Zuk P.A., Zhu M. and Mizuno H.: Multilineage cells from human adipose tissue: Implications for cell-based therapies. *Tissue Eng.*, 7: 211-228, 2001.
- 5- Zhu M. Zhou Z. and Chen Y.: Supplementation of fat grafts with adipose derived regenerative cells improves long terms graft retention. *Ann. Plast. Surg.*, 64: 222-228, 2010.
- 6- Colman S.R., Coleman S.R. and Mazzolla R.F.: Compilers. In: *Updates on structural fat grafting, Fat injection: From filling to regeneration*. St. Louise: MO: Quality Medical Publishin, pp. 93-203, 2008.
- 7- Pietrzak W.S. and Eppley B.L.: Platelet rich plasma: biology and new technology. *J. Craniofac. Surg.*, 16: 1043-1054. [PubMed], 2005
- 8- Kakuda N., Minakata T. and Mitsui T.: Proliferation promoting effect of platelet-rich plasma on human adipose-derived stem cells and human dermal fibroblast. *Plast. Reconstr. Surg.*, 122: 1352-1360, 2008.
- 9- Coleman S.R.: Facial recontouring with lipostructure. *Clin. Plast. Surg.*, 24: 347-367, 1997.
- 10- Cervelli V., Nicoli F. and Spallone D.: Reatment of traumatic scars using fat grafts mixed with platelet-rich plasma, and resurfacing of skin with the 1540nm nonablative laser. *Clinical & Experimental Dermatology*, 37: 55-61, 2012.
- 11- Marx R.E.: Platelet rich plasma: Evidence to support its use. *J. Oral Maxillofac. Surg.*, 62: 489-496, 2004.
- 12- Cervelli V., Gentile P. and Scioli M.G.: Application of platelet rich plasma in plastic surgery: Clinical and in vitro evaluation. *Tissue Eng Part C Methods*, 15: 625-634, 2009.
- 13- Cervelli V., Palla L., Pascali M., De Angelis B., Curcio B.C. and Gentile P.: Autologous platelet-rich plasma mixed with purified fat graft in aesthetic plastic surgery. *Aesthetic Plast. Surg.*, 33: 716-21, 2009.
- 14- Modarressi A.: Platlet Rich Plasma (PRP) Improves Fat Grafting Outcomes. *World J. Plastic Surg. Jan.*, 2 (1): 6-13, 2013.
- 15- Nita A.C., Orzan O.A., Fillipescu M. and Jianu D.: Fat graft, Laser Co2 and Platelet Rich Plasma Sunergy in scar treatment, *Journal of Medicine & life Vol.*, Issue 4, October-December, pp. 430-433, 2013.